



# INFECTIOUS LARYNGOTRACHEITIS (ILT) IN POULTRY

Technical Bulletin

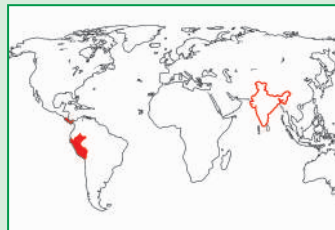Vol. 3

June, 2010

Infectious Laryngotracheitis is a highly contagious viral infection of respiratory tract of chicken caused by a herpes virus. Morbidity due to this disease is almost 100% and mortality ranges between 10-70%, depending upon the virulence of the virus strain. Infectious Laryngotracheitis is found in broilers of more than 3 weeks of age and in pullets of more than 7 weeks of age. Incubation period of Infectious Laryngotracheitis virus ranges from 5 to 10 days.

## Prevalence :

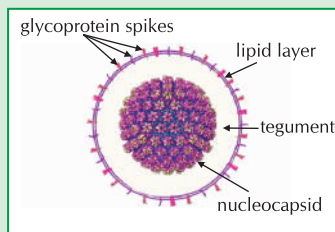
The official status of the disease can be understood from Handistatus presentation of OIE. Considering the information available on these sites, prevalence of Infectious Laryngotracheitis was restricted to Peru and Panama (period 2005-2009). A search on Handistatus reveals that outbreak of Infectious Laryngotracheitis has taken place in India for the first time in 1997.



ILT prevalence in the world

## Virus :

Infectious Laryngotracheitis virus is classified as a member of the family *Herpesviridae*, subfamily *Alphaherpesvirinae*. The virus is taxonomically identified as *Gallid herpesvirus 1*.



Structure of Laryngotracheitis Virus

It is an enveloped DNA virus which has a diameter of 195-250 nm and consists of an irregular envelope surrounding the nucleocapsid. The envelope contains viral glycoprotein spikes as fine projections on its surface. It contains five major glycoprotein spikes which are reported to be the major immunogens of Laryngotracheitis virus. Different types of Infectious Laryngotracheitis virus strains are available in nature which varies in their virulence. The manifestation of virulence among strains varies from mild/ in-apparent infection to high morbidity and mortality.

Trigeminal ganglion in chicken is the main site of latency of Infectious Laryngotracheitis virus.

## Transmission, Carriers, Vectors :

Natural portals of entry for Laryngotracheitis virus are through upper respiratory tract, ocular route and oral ingestion. Transmission occurs more readily from acutely infected birds than through contact with clinically recovered birds.

The coughed-up mucosa and blood of the infected bird are the medium through which this disease spreads. Feathers, shed dust, feed trucks, human beings, contaminated equipment and litter are the ideal transporting agents. There is no vertical transmission of the virus from breeders to chicks.

Infectious Laryngotracheitis is not transmissible to human beings.

## Clinical symptoms :

In case of an outbreak, there is a spiking mortality among the flock. Severity of the disease and mortality rate varies widely among outbreaks and depends on the following factors:

- Age of the birds
- Immune status of the flock
- Virulence of the virus strain
- Viral load on the farm
- Concurrent infection with other respiratory pathogens; and
- Harsh environmental factors that adversely affect the respiratory system

Clinical symptoms noticed during different forms of severity of the disease:

### Per-acute form :

Infected birds are lethargic, have swollen eye-lids followed by ocular discharge. Birds exhibit mouth breathing, coughing & emit respiratory noises. Some birds stretch out their neck while trying to breathe & cough-up blood stained mucus. Mortality may be as high as 70%.



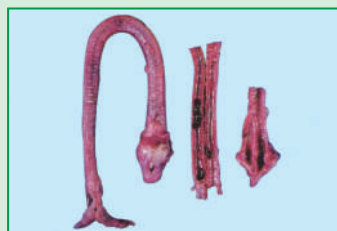Breathing through mouth

**Acute form:** There are less severe respiratory rates & coughing with expulsion of caseous material, mucoid nasal discharge, gasping and swollen eyelids. Mortality may range from 10-30%.

**Chronic form :** The birds are drowsy with signs of conjunctivitis, squinting eyes and cough. Morbidity is as low as 5%. There is often a concurrent infection with coryza. Egg production may drop to 10%.

**Post-mortem findings :**

In the per-acute form, post-mortem lesions are limited to the upper respiratory tract and consist of hemorrhagic tracheitis with blood clots. Lumen of the trachea is blocked by mucoid blood clots or sometimes by yellow caseous exudate (cheesy plug).



Blood clots in trachea

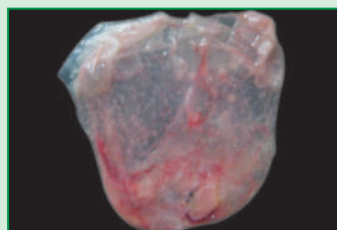
In the acute form, lesions consist of mucoid exudate with or without blood in the trachea. Yellow caseous diphtheritic membranes may be found adherent to the larynx and upper tracheal mucosa. In both acute and sub-acute form, death is due to suffocation.

In the chronic form, false membrane is found in the upper respiratory tract and causes death.

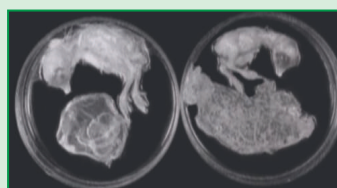
**Diagnosis :**

- Clinical signs and post-mortem lesions are the basis for diagnosis of the disease.
- Confirmatory test is done through embryo inoculation method.

Suspected virus material collected from tracheal swab of infected birds is inoculated in chick embryos of 11<sup>th</sup> to 12<sup>th</sup> day of age. The route of inoculation is chorio-allantoic membrane (CAM). Three days post inoculation, plaques can be observed on CAM. These plaques have opaque edges and depressed central area of necrosis. The size of surviving embryo also gets reduced.



CAM showing poek like lesions, 4-5 days post infection



14 days embryo. Normal embryo and CAM (left). ILT infected stunted embryo and CAM showing poek like lesions (right)

**Prevention and Control :**

There is no treatment for Infectious Laryngotracheitis. To prevent and control Infectious Laryngotracheitis, we need:

- Sound bio-security and sanitation
- Effective vaccination of parents and progeny

Infectious Laryngotracheitis virus can survive for 10 days or more in droppings and up to 70 days in carcasses at ambient temperature of 13°C to 23°C. The virus lasts

longer in winter. It appears that the virus may survive up to 80 days in tracheal mucus on non-conductive material such as wood. However, the disease keeps perpetuating on the farm because of healthy carriers.

To get rid off Infectious Laryngotracheitis virus from a poultry farm, it is necessary to practice following after cleaning the empty shed:

- Sunlight, heat and drying (virus gets inactivated at 38°C within 48 hours)
- A mist created by 5% hydrogen peroxide in the shed
- Cresol 3% or lye 1% solution- apply on floors and walls

Apart from this, biosecurity should also include restricted entries, cleaning up of surfaces, disposal of carcasses, rodent control, insect and pest control, personnel hygiene, disinfection of vehicles, egg trays etc.

**Vaccination:**

The maternal antibodies have no protective role in case of Infectious Laryngotracheitis. It is therefore, necessary to confer active immunity to all birds of all ages by following proper vaccination schedule:

**Live Vaccines :**

Although live vaccines are available, the disadvantages of using live vaccines are :

- The reversion of virulence is seen with all the available live vaccines.
- These viruses become latent in the trigeminal ganglion and get activated when birds are under stress and perpetuate Infectious Laryngotracheitis virus in susceptible poultry flocks.

**Inactivated Vaccines :**

Inactivated vaccines have been used to control Infectious Laryngotracheitis. This is a safe method of control. These vaccines have shown to stimulate the desired immune response in chicken.



Committed to Provide Appropriate Solutions to Poultry Disease Problems.

INDOVAX Private Limited

Corporate Heights, SCO-24, Sector-14, Gurgaon 122 001 (INDIA)

Tel : +91-124-231 5044, 231 5045, 231 5046,

Fax : +91-124-231 4680

E-mail : marketing@indovax.com,

Website : www.indovax.com